Dermatopathology Slide Review Part 27

Paul K. Shitabata, M.D.
Dermatopathology Institute

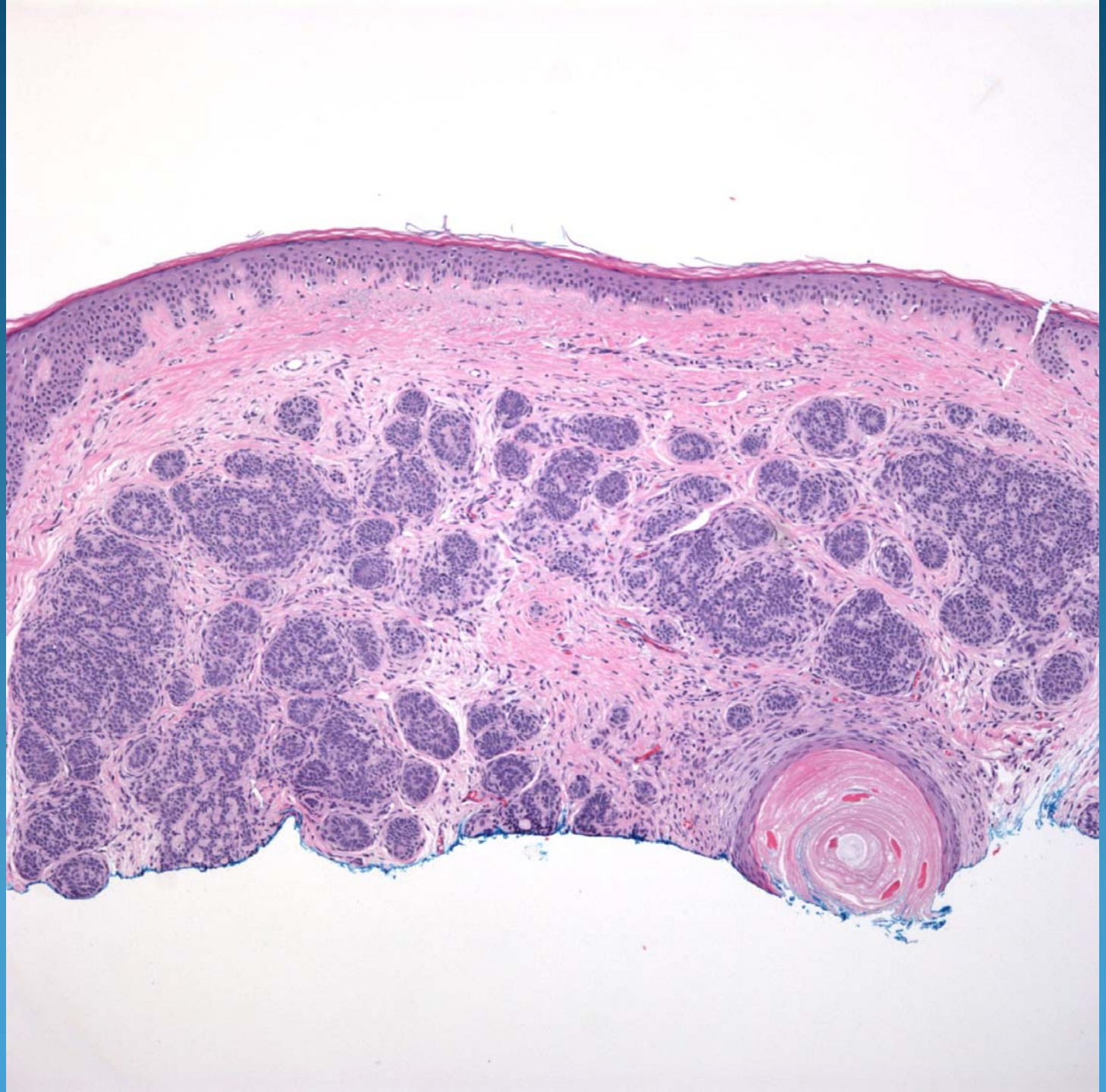

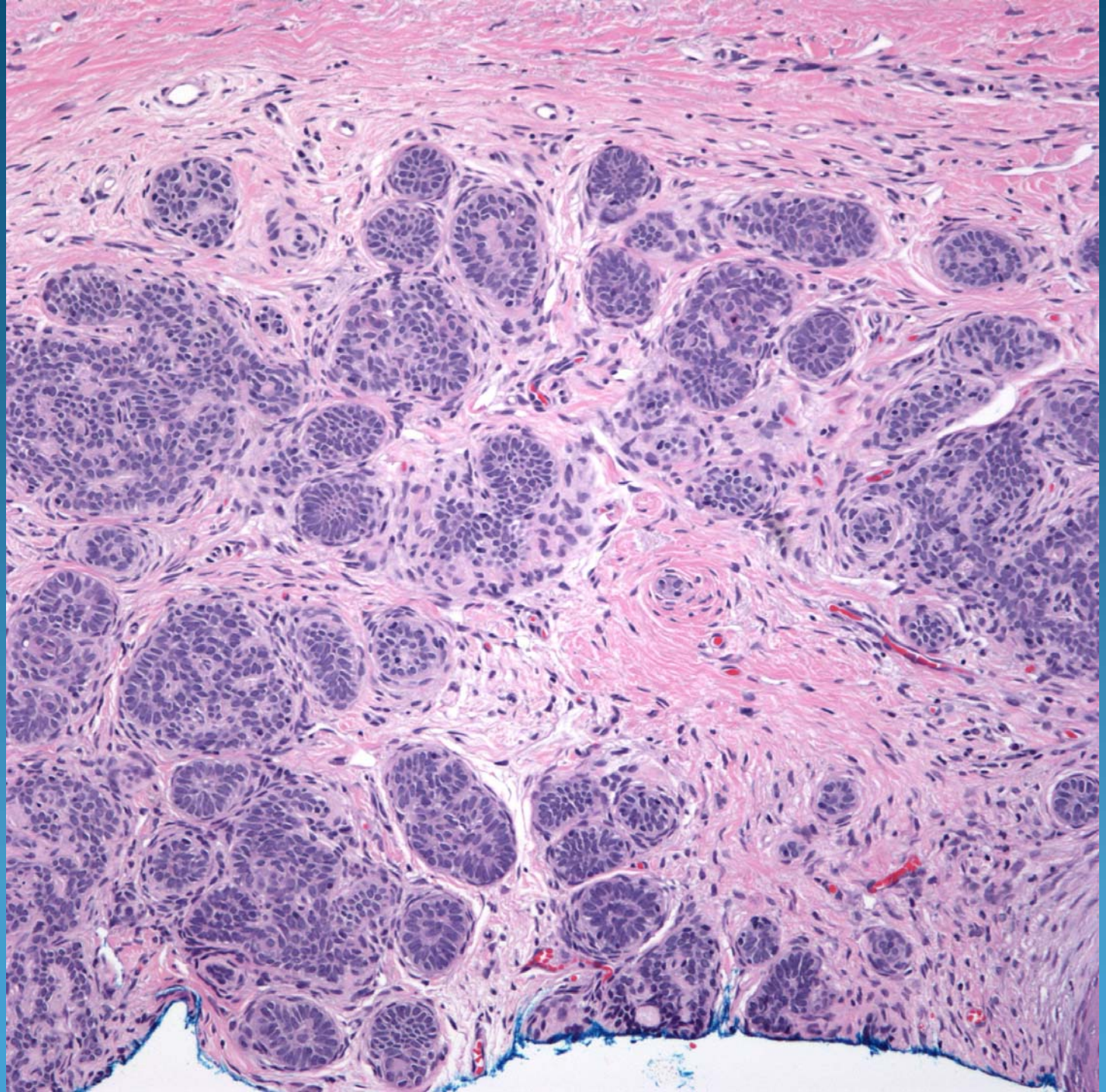

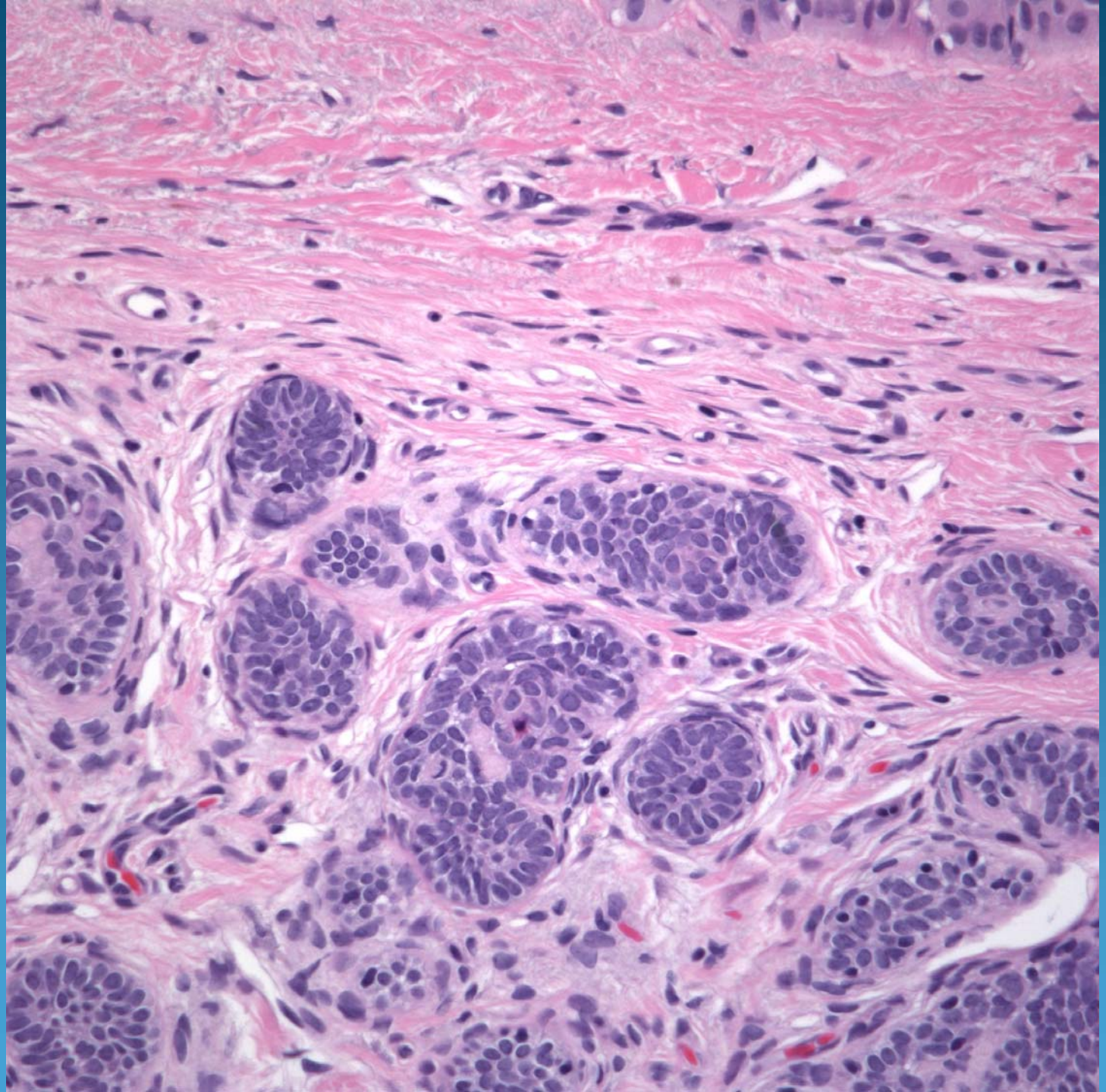

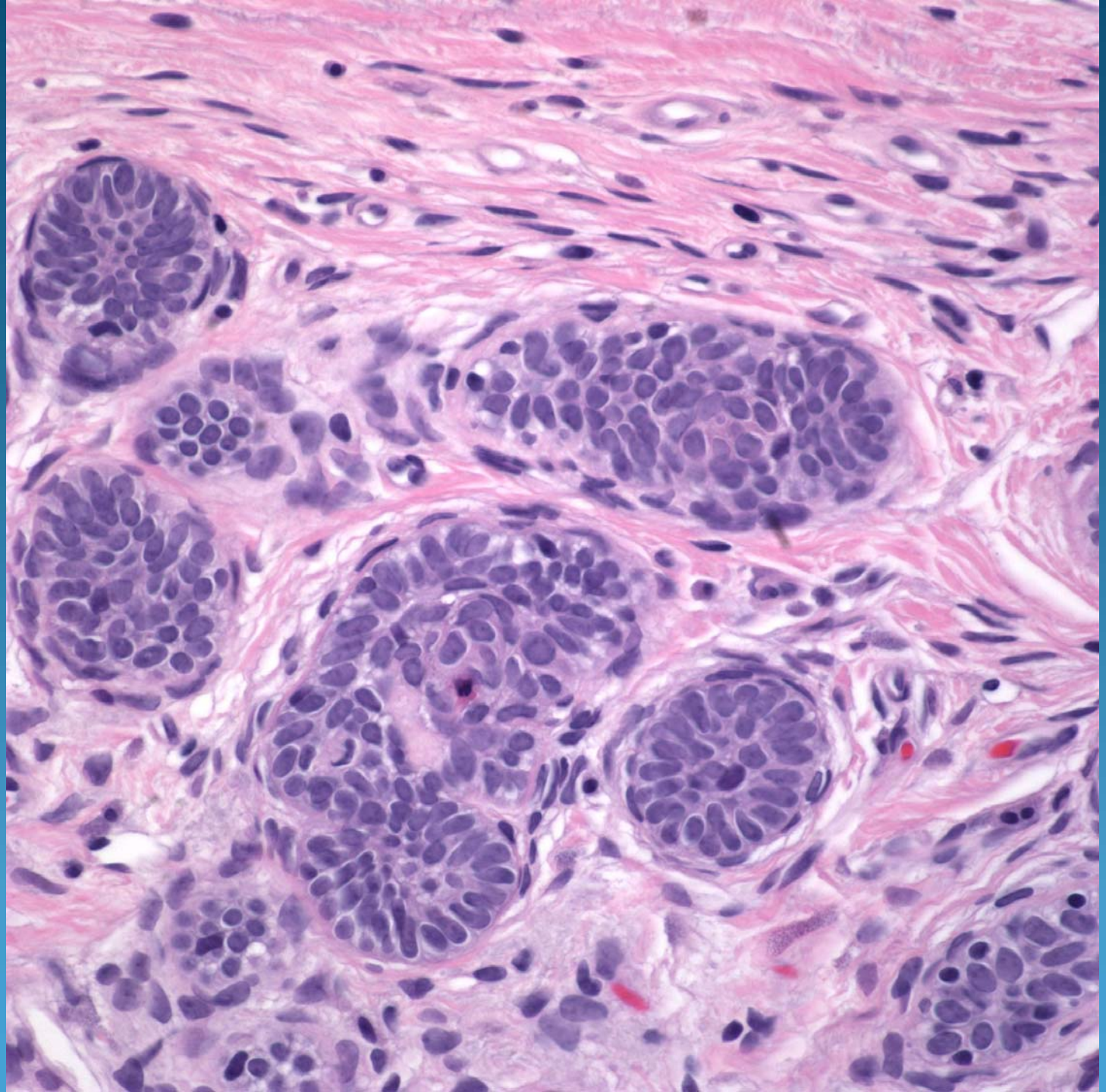

Trichoepithelioma

Pearls

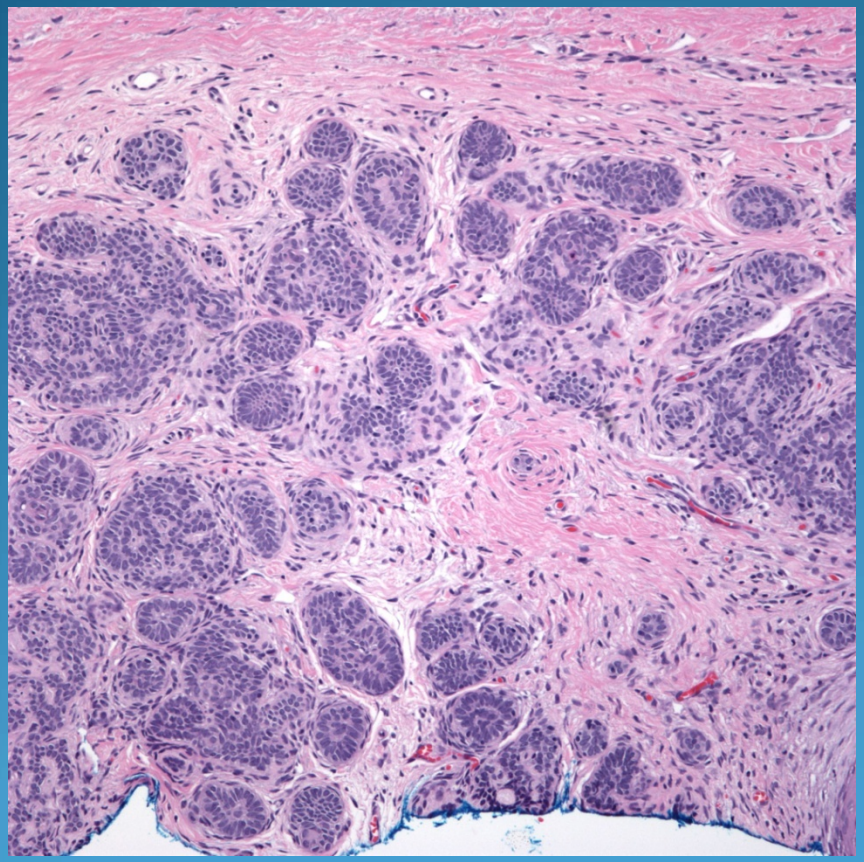

- Dermal based proliferation of basaloid cells
- Stromal-stromal clefting
- Usually no epidermal attachment
- Papillary-mesenchymal bodies

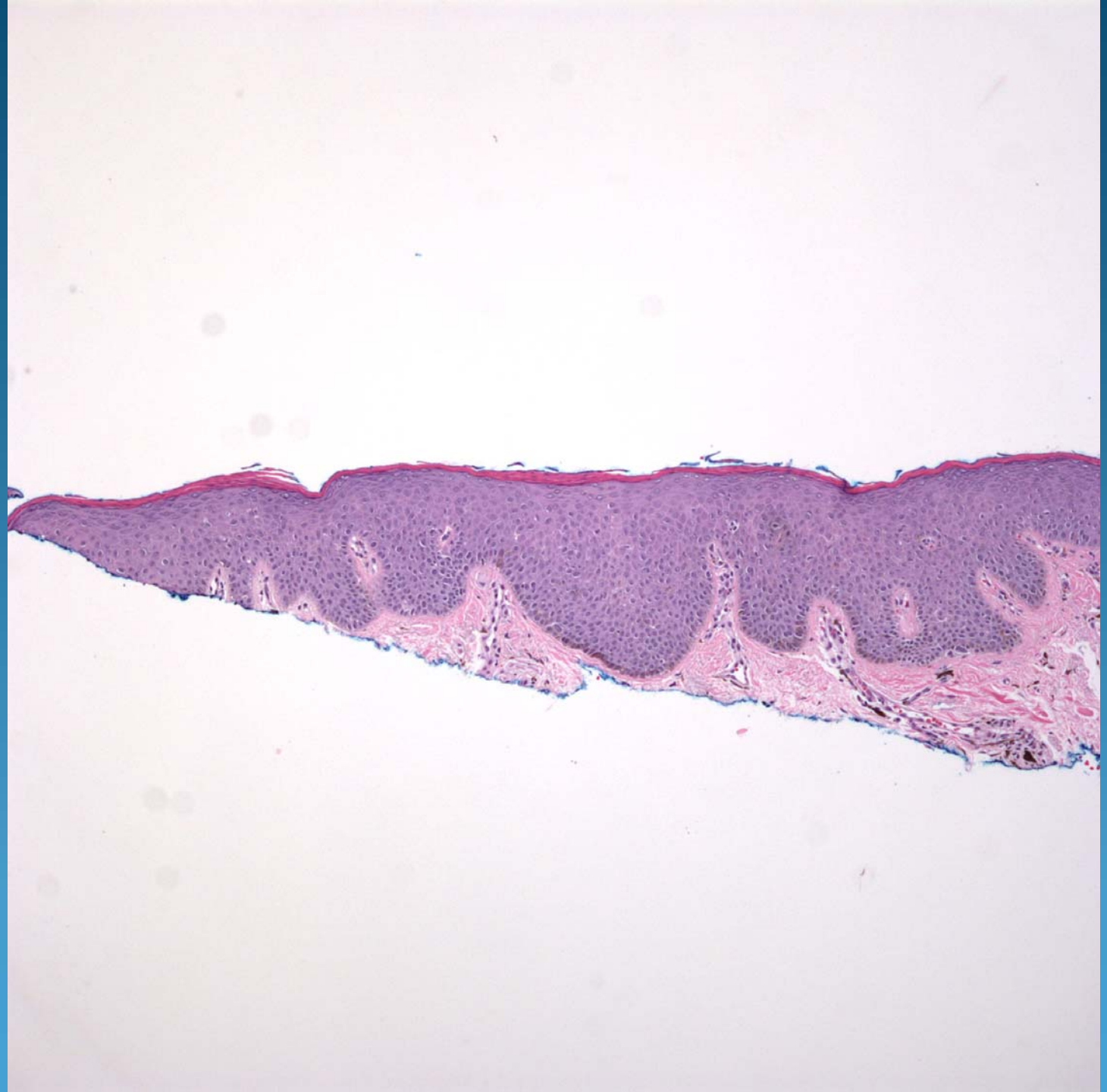

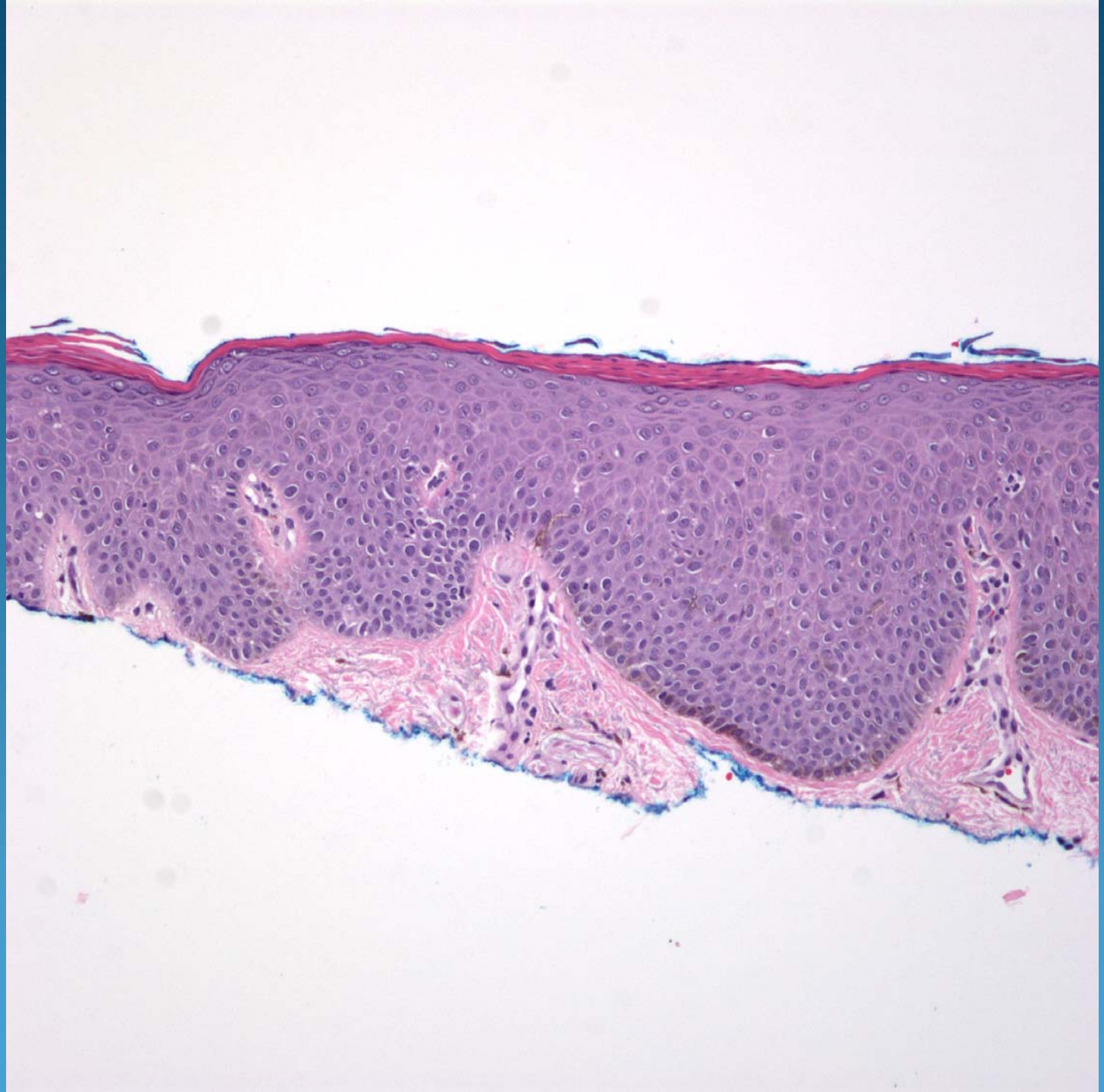

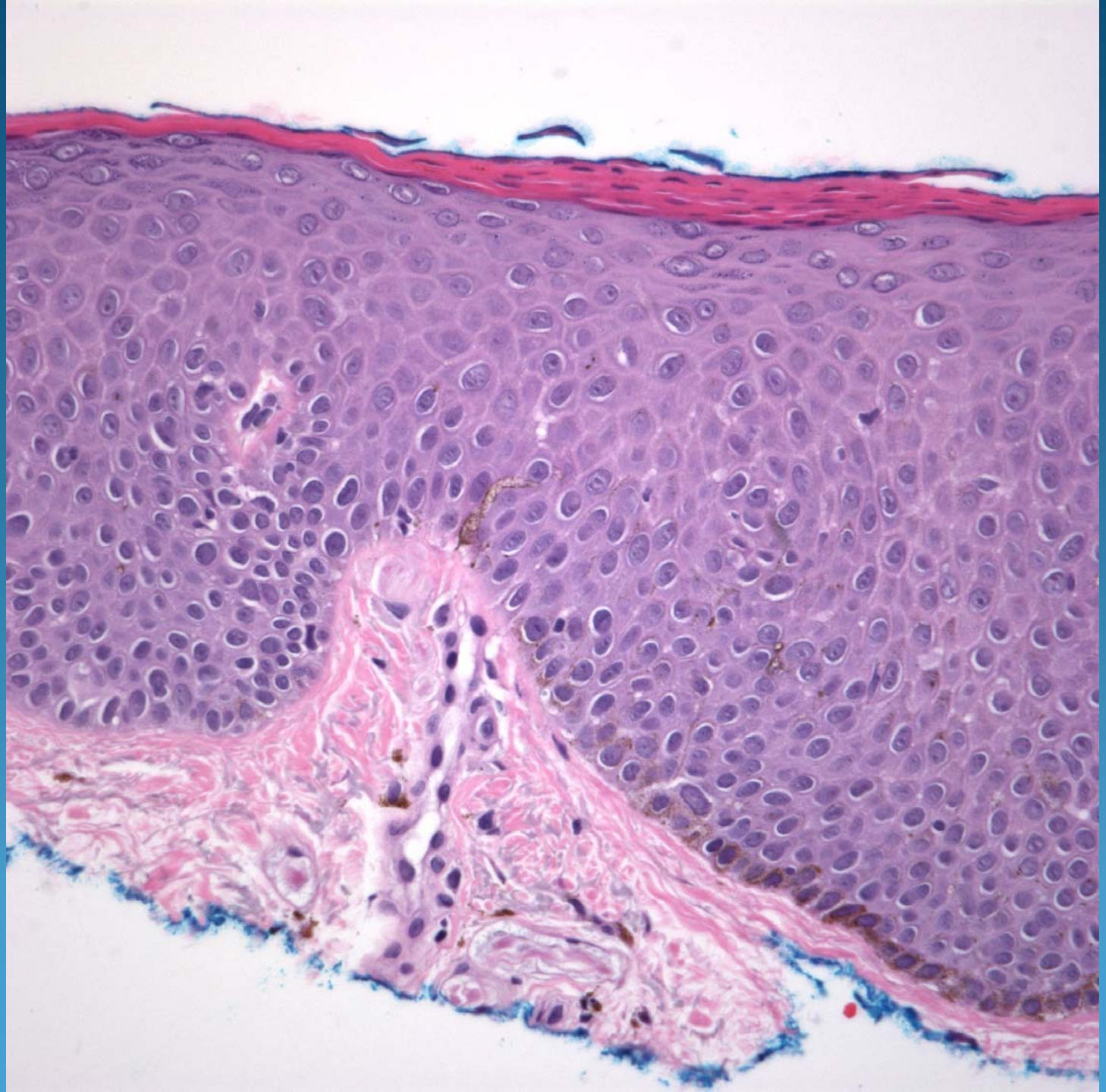

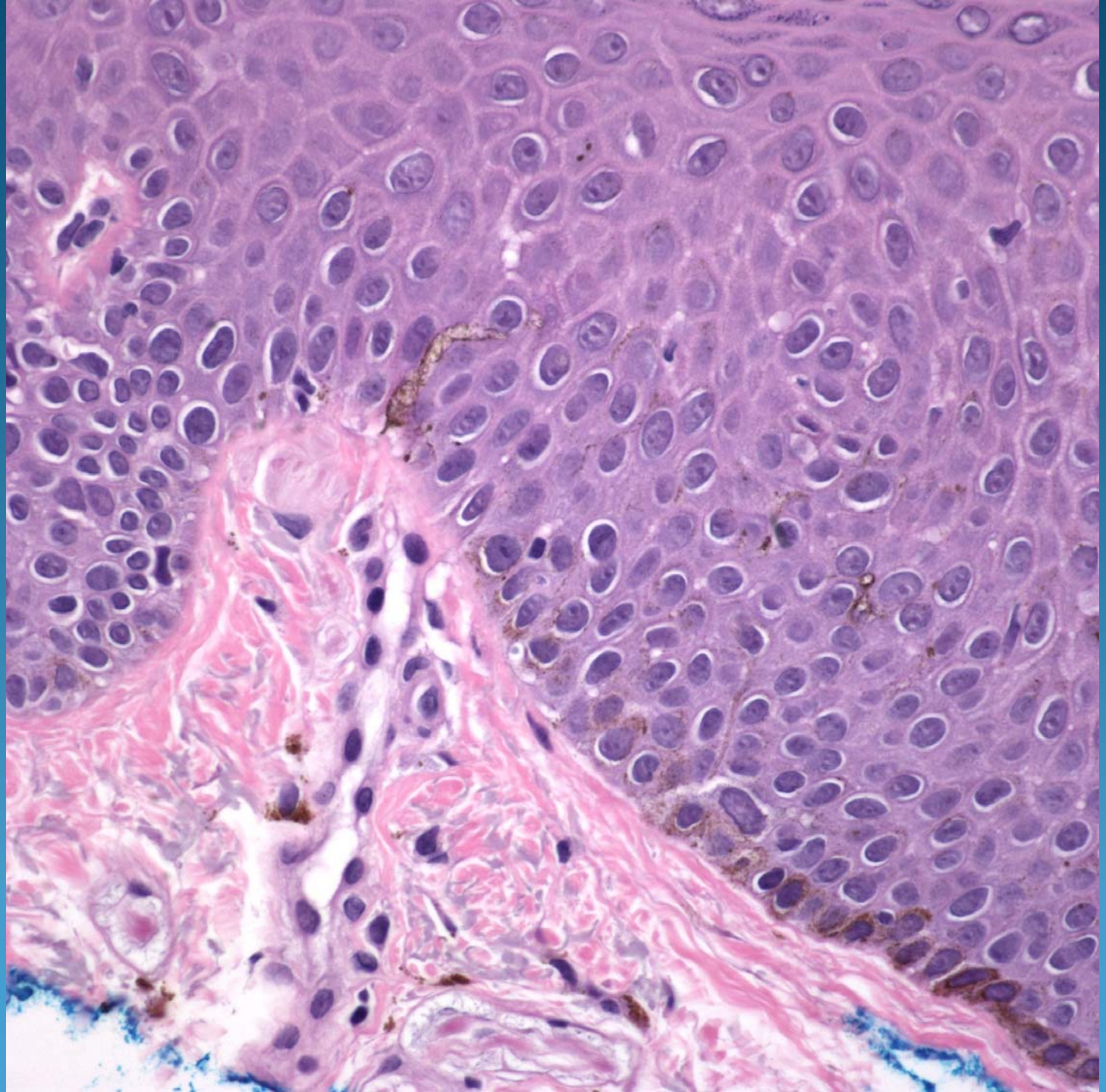

Mucosal Lentigo
(Labial Melanotic Macule)

Pearls

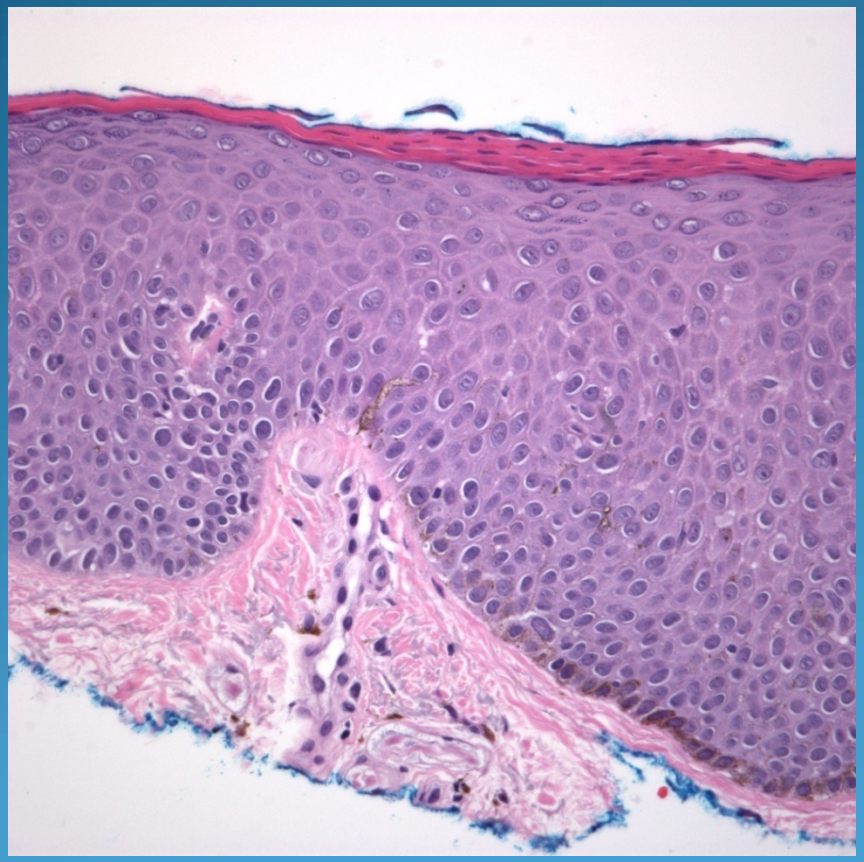

- Melanin hyperpigmentation at the basal epithelial layer
- Unassociated with increase in melanocytes
- Compare adjacent non-pigmented mucosa for confirmation

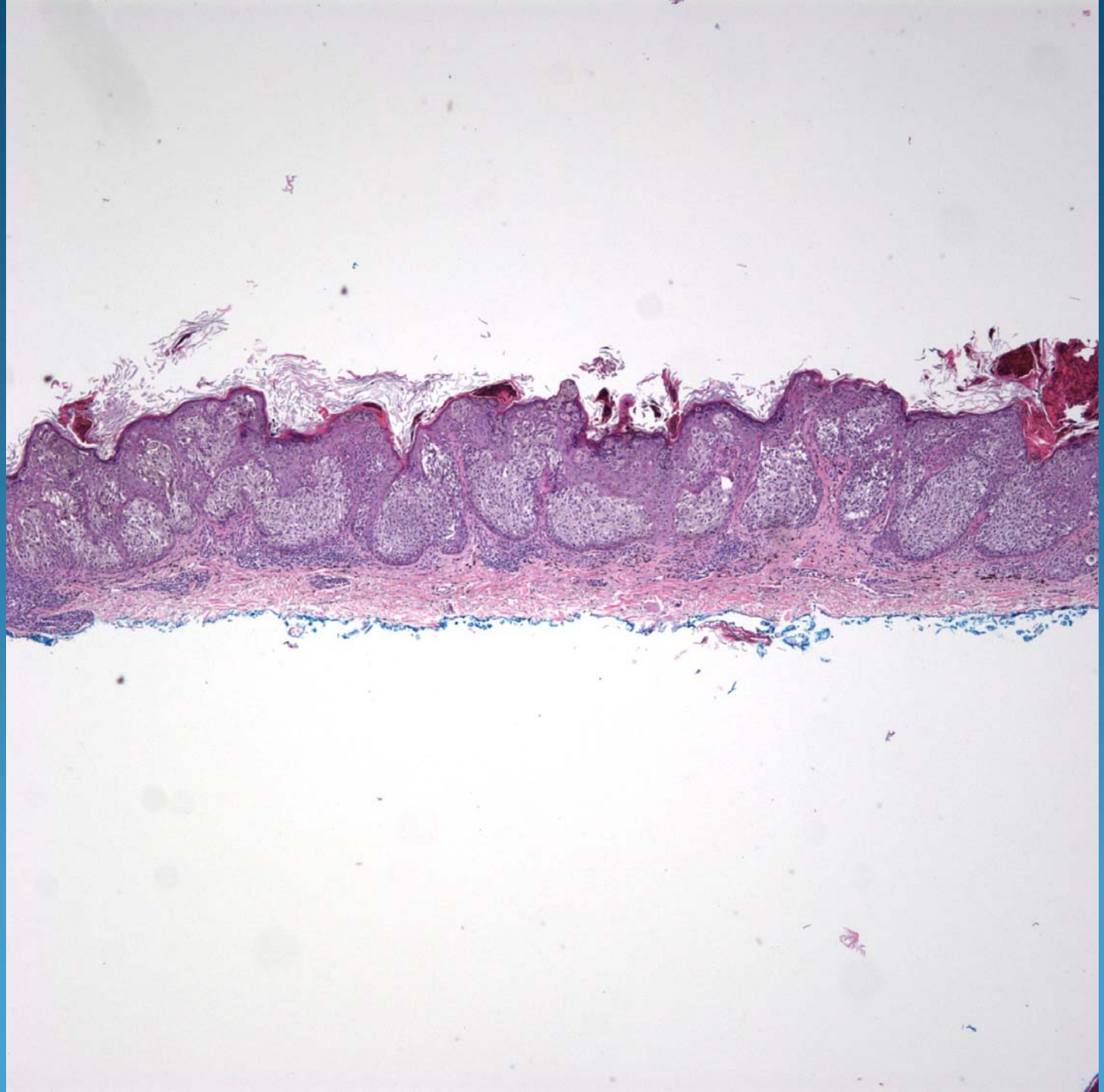

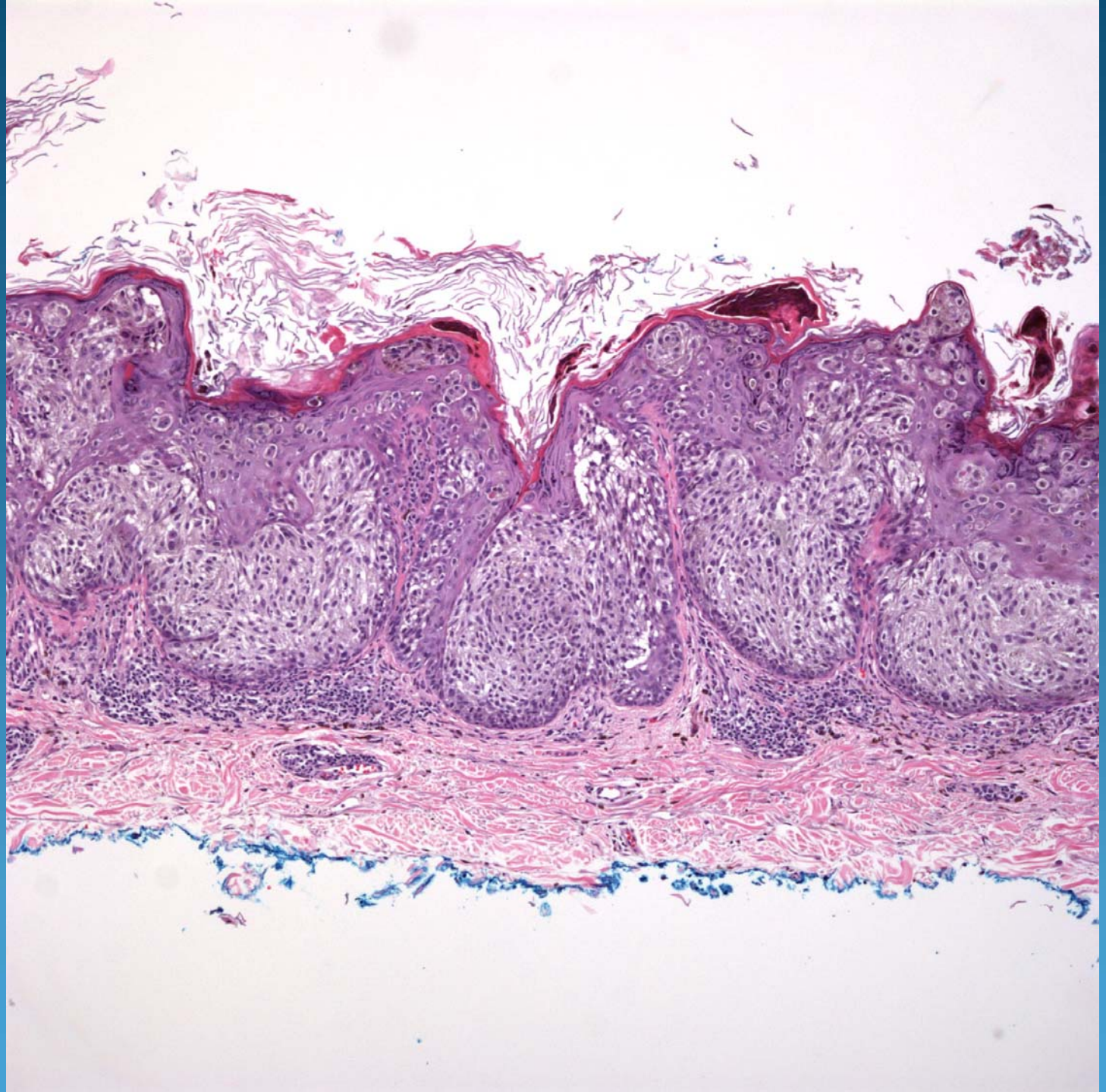

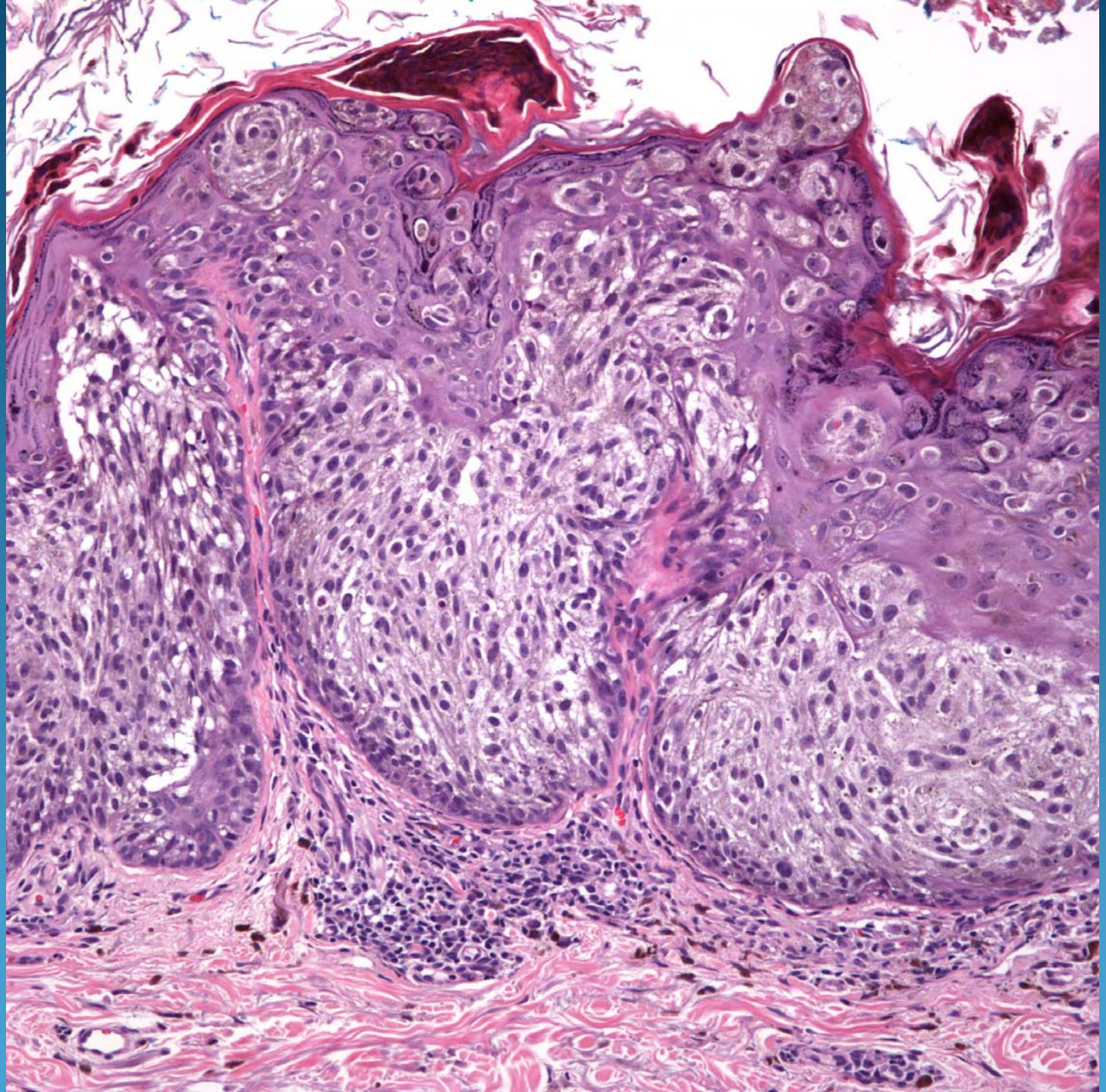

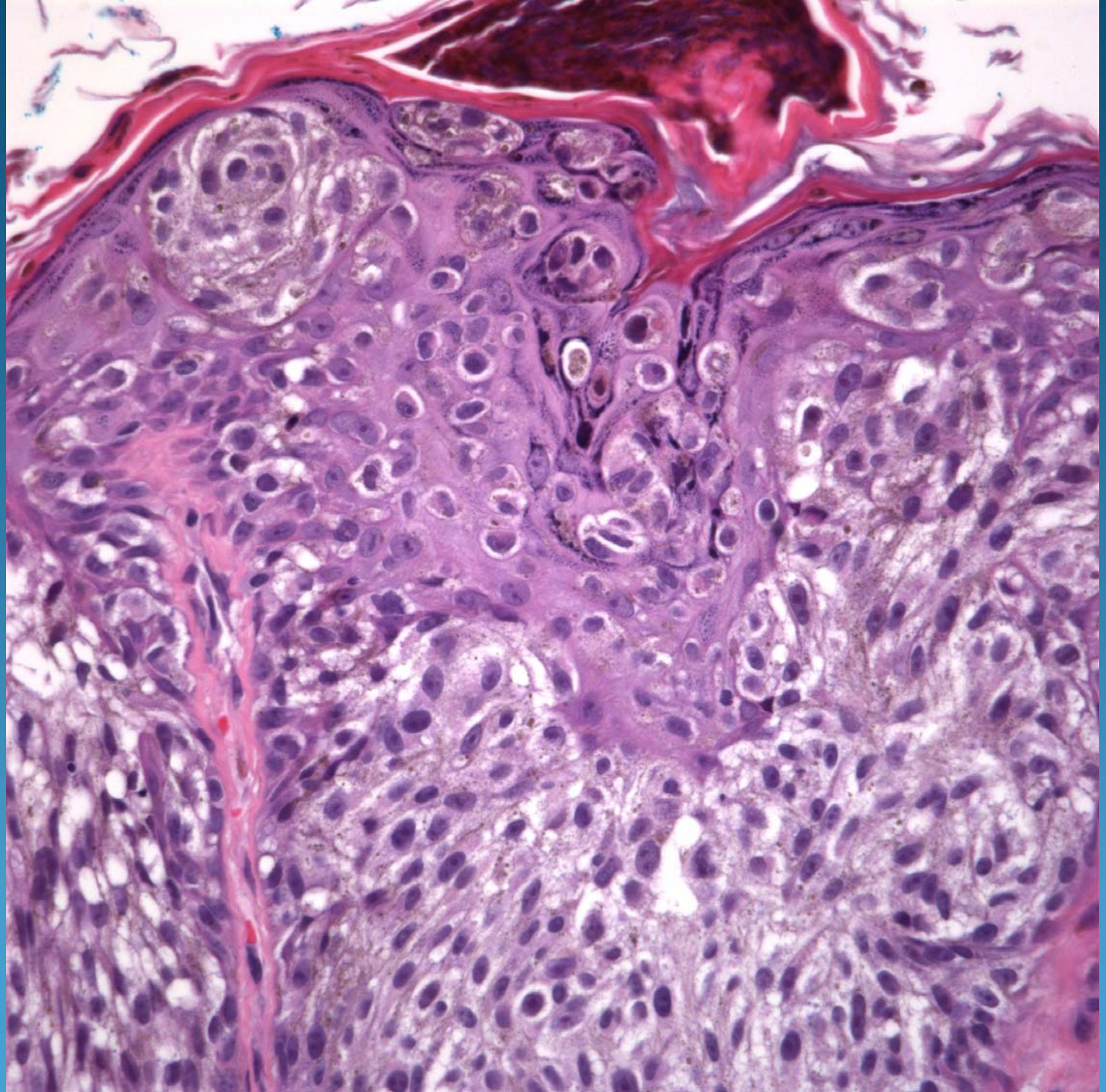

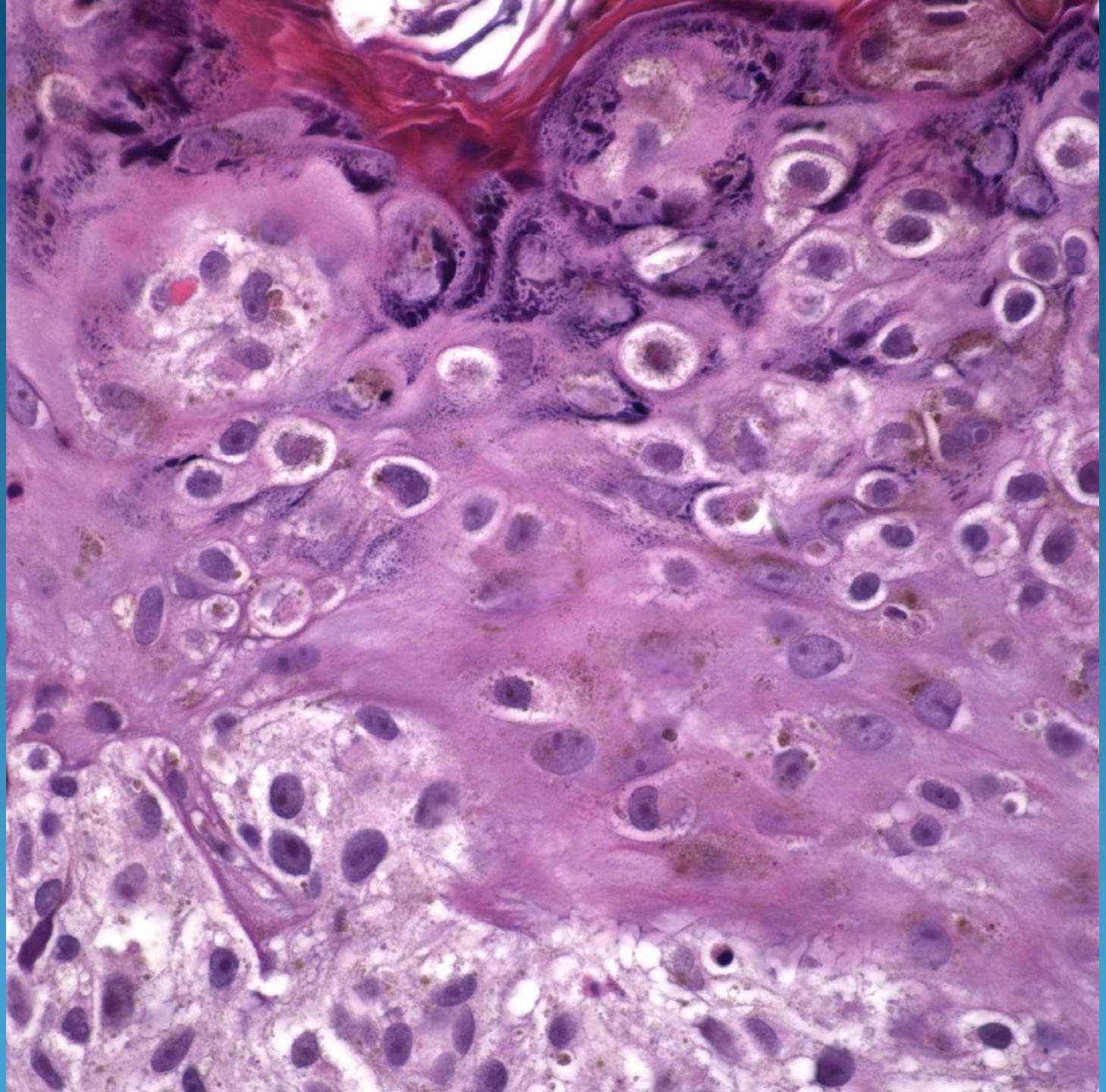

Malignant Melanoma, Superficial Spreading Type

Pearls

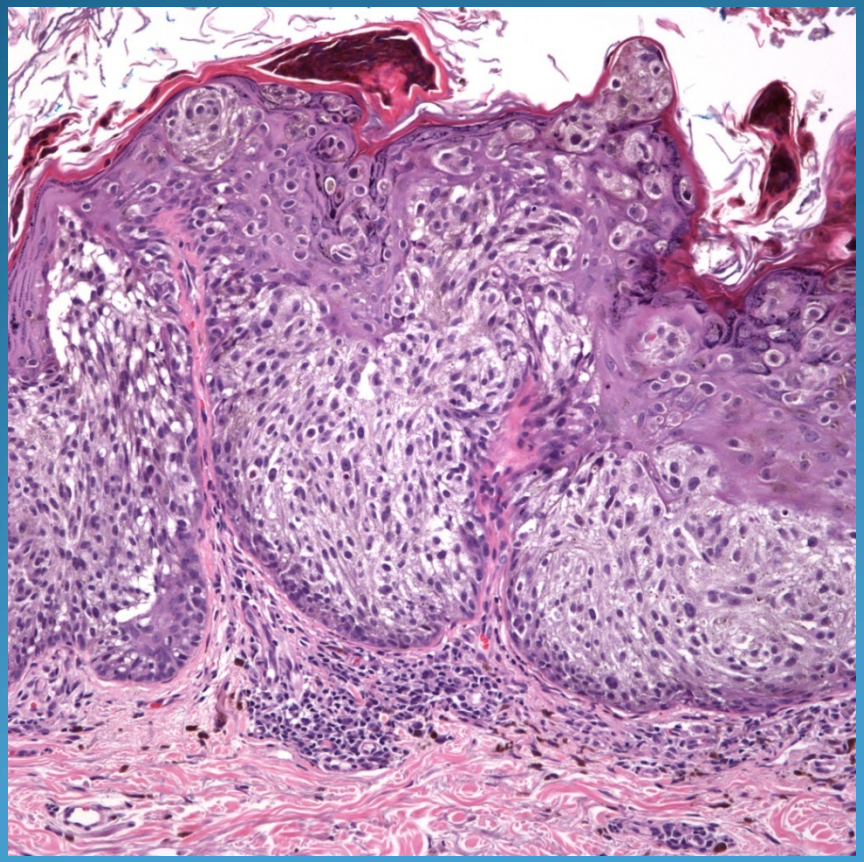

- Cytologically malignant melanocytes with upward intraepithelial scatter (Pagetoid spread, buckshot pattern)
- May be combined with other melanoma variants
- Poor peripheral circumscription

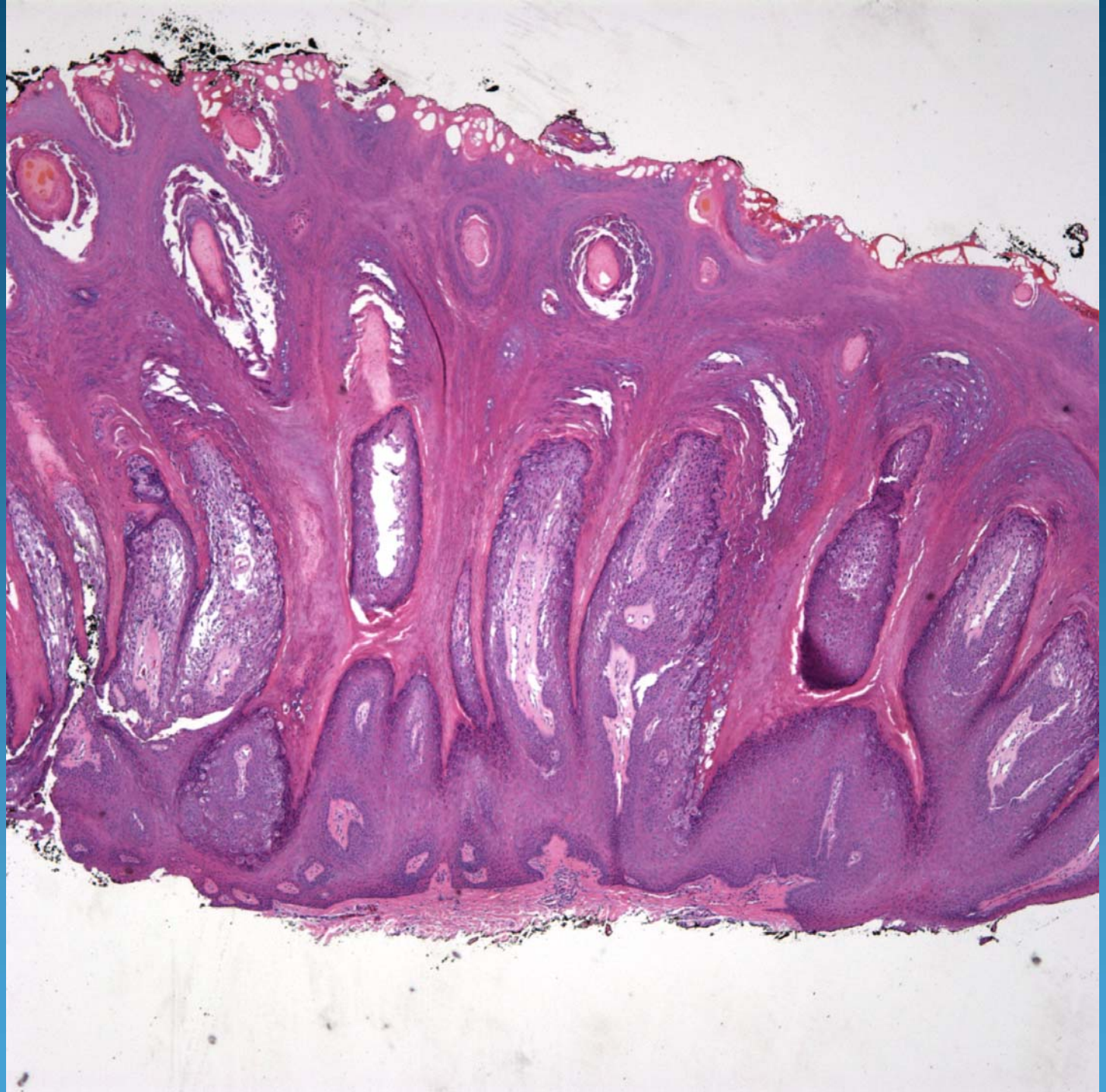

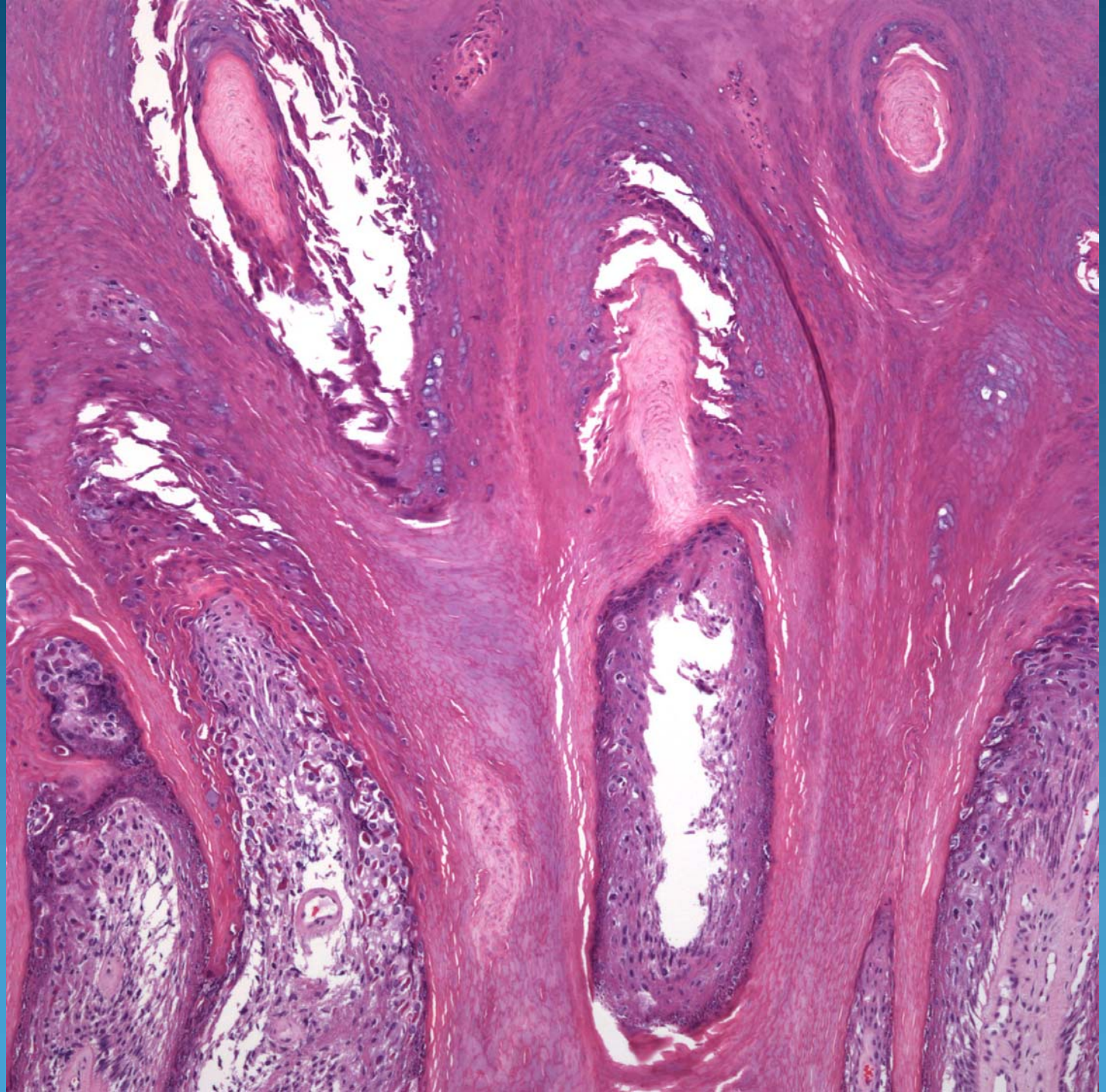

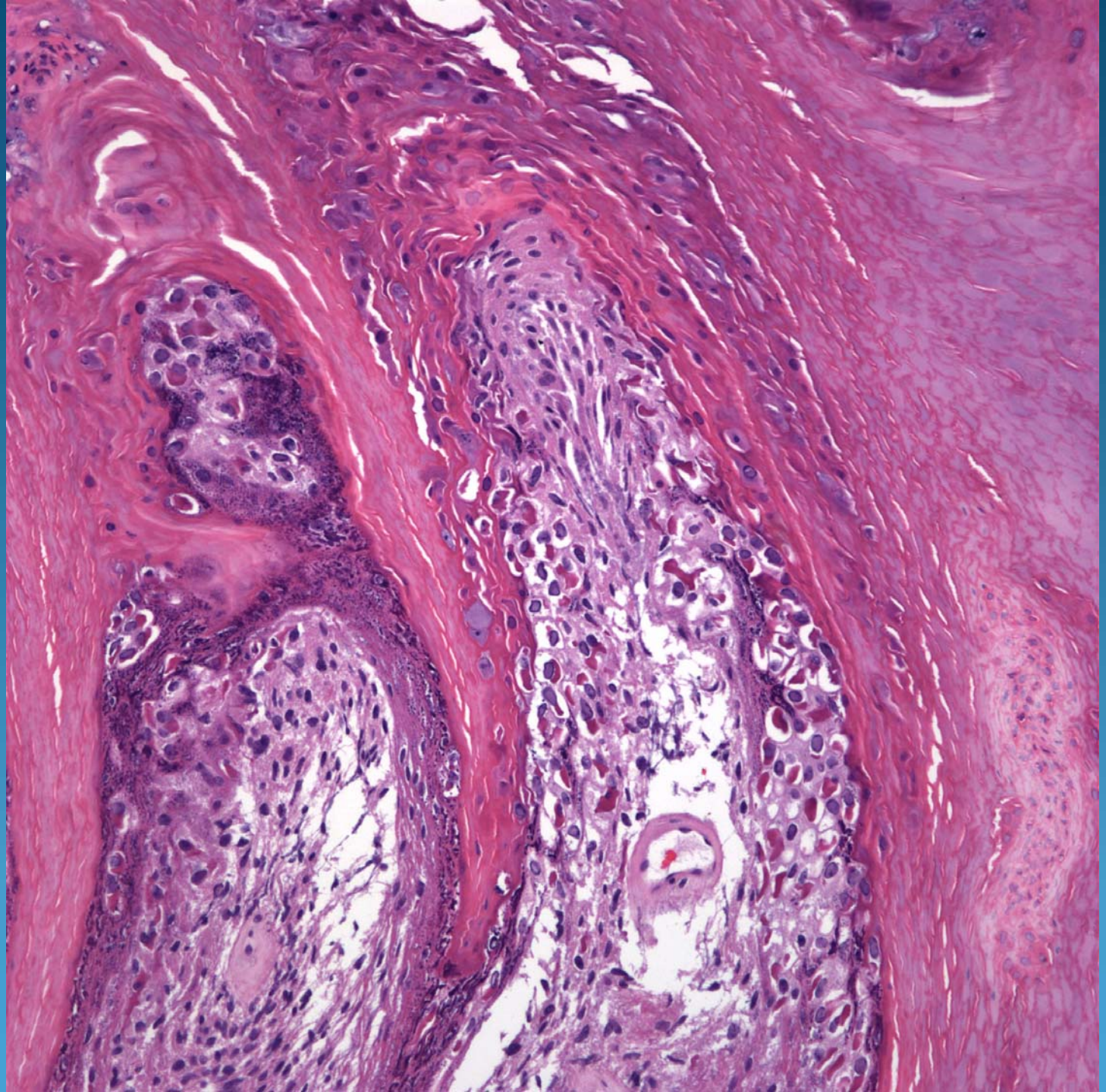

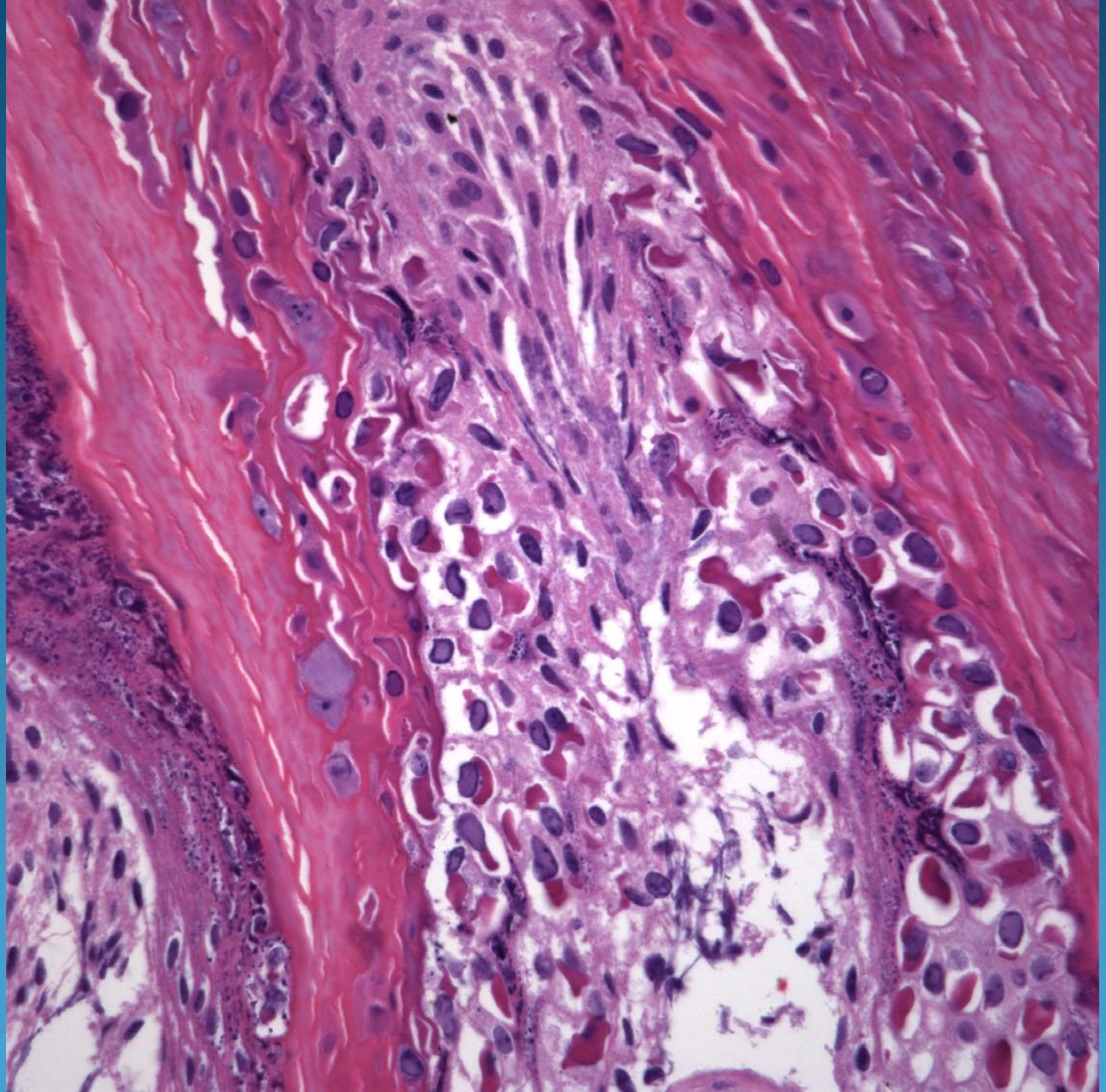

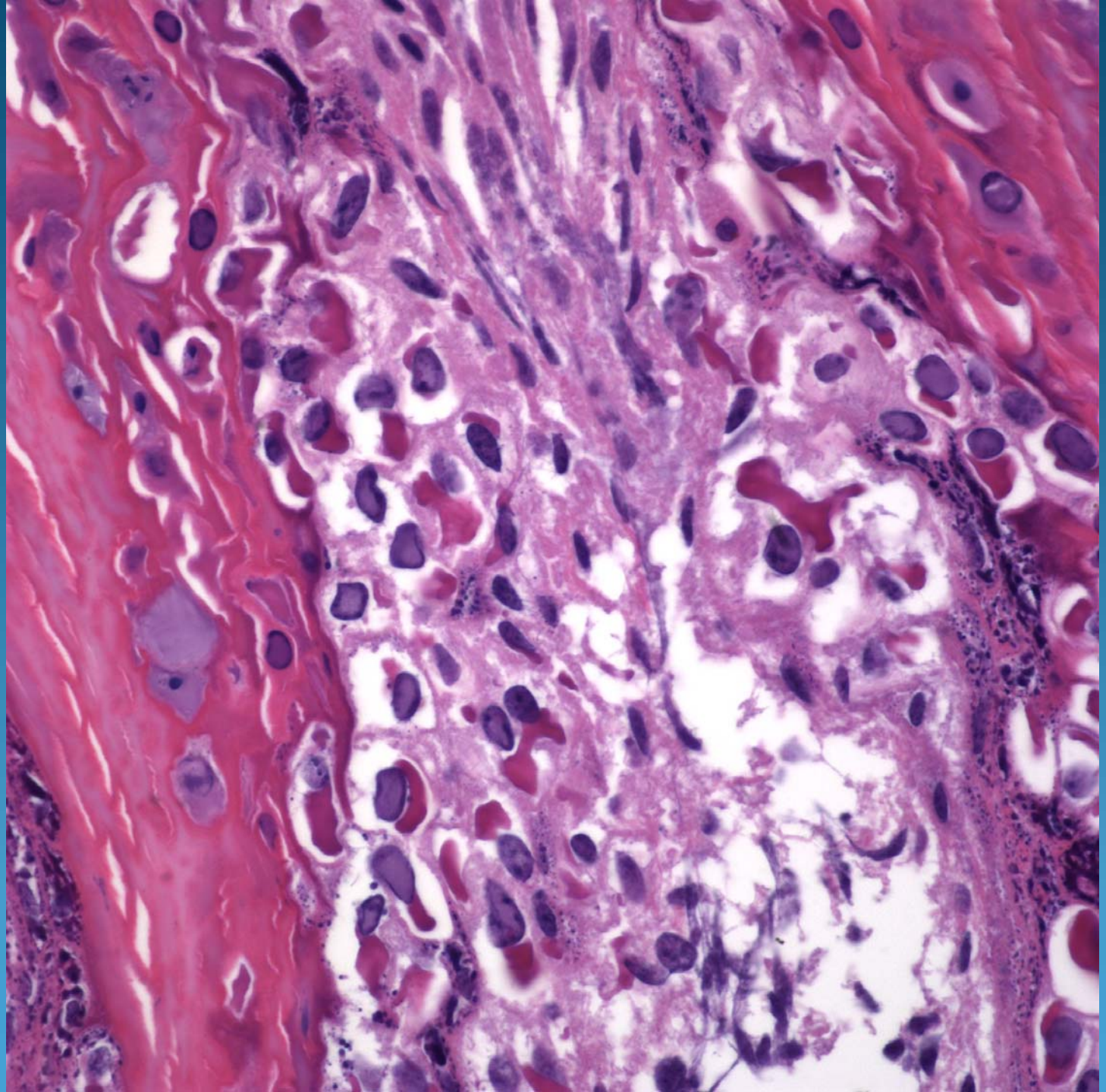

Verruca Vulgaris

Pearls

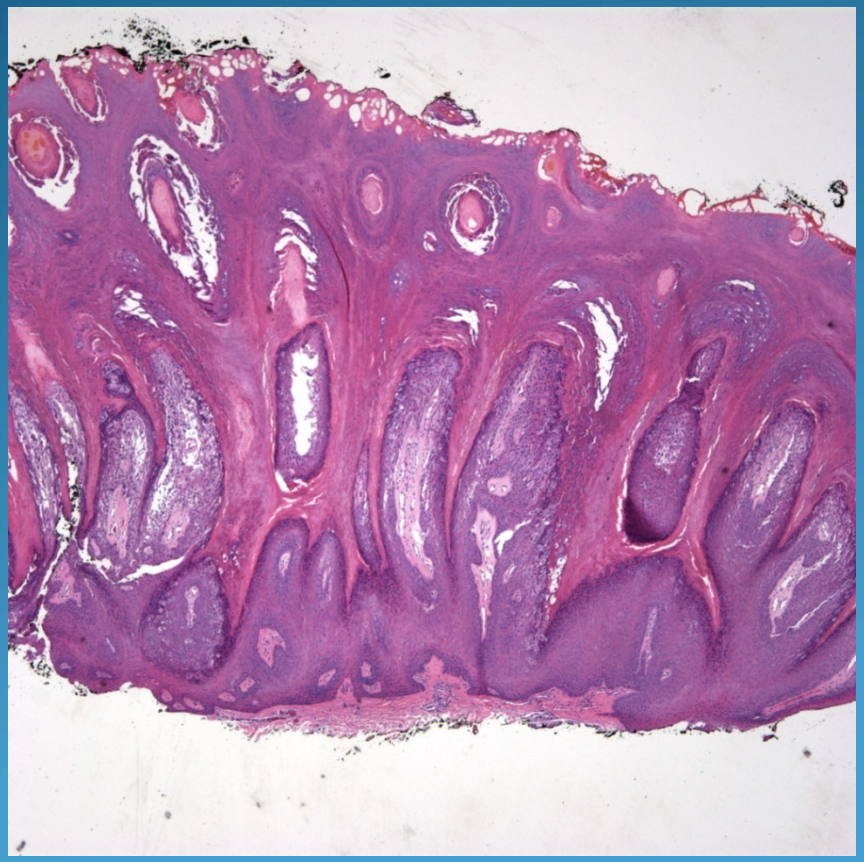

- Finger-like (papillomatous) projections
- Inward bending of rete ridges
- Columns of parakeratosis
- Koilocytosis
- Eosinophilic cytoplasmic viral inclusions

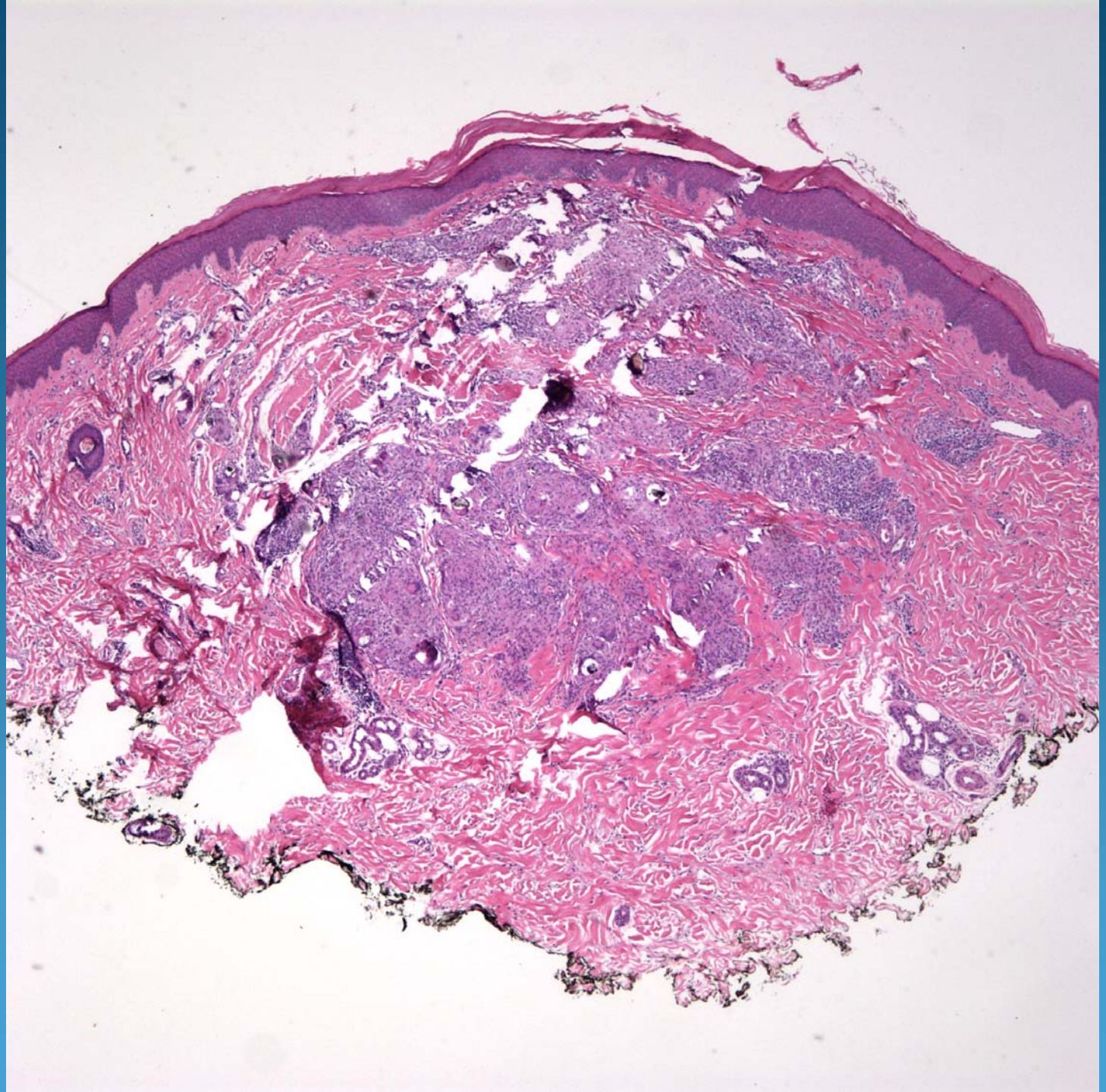

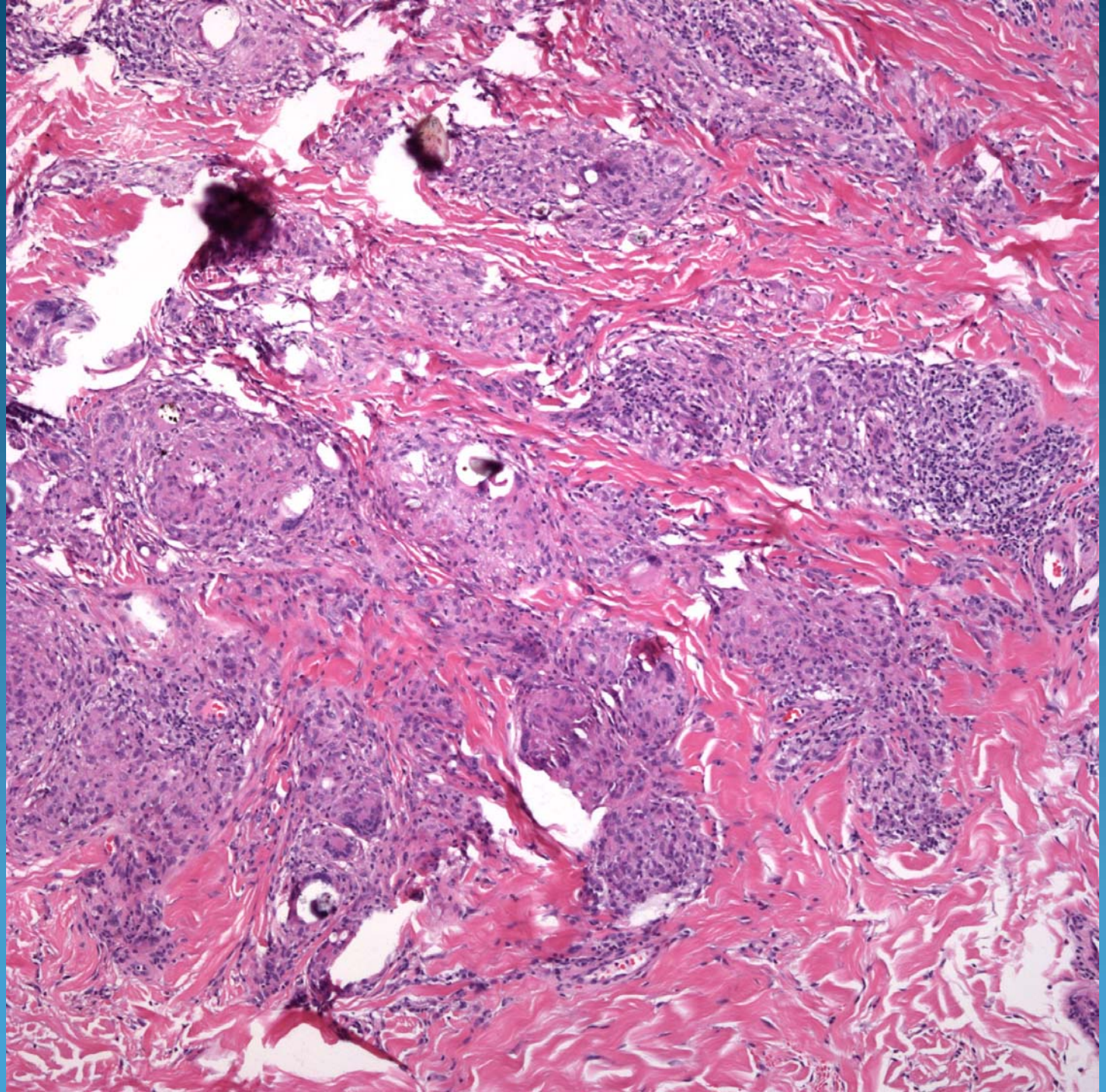

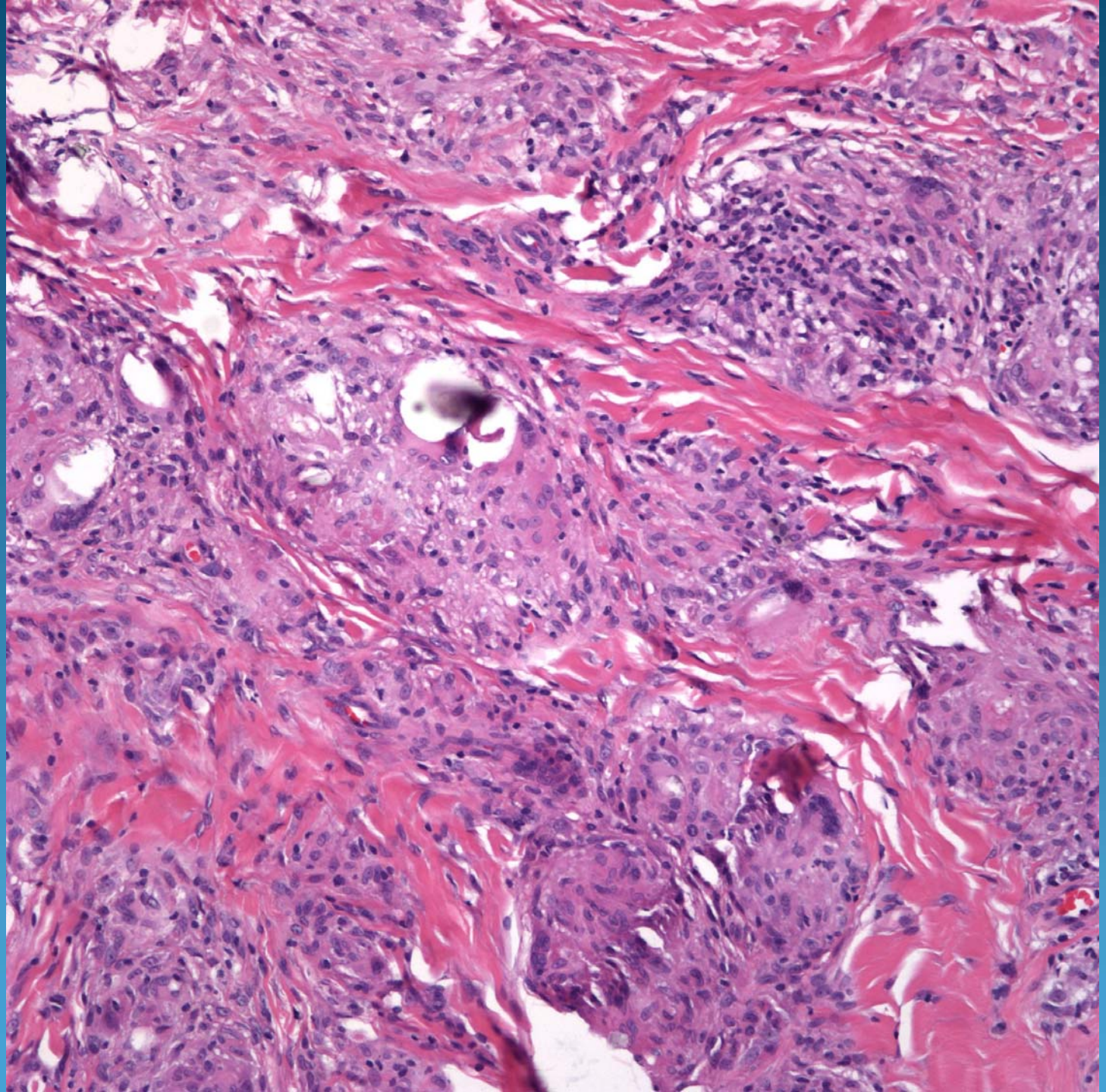

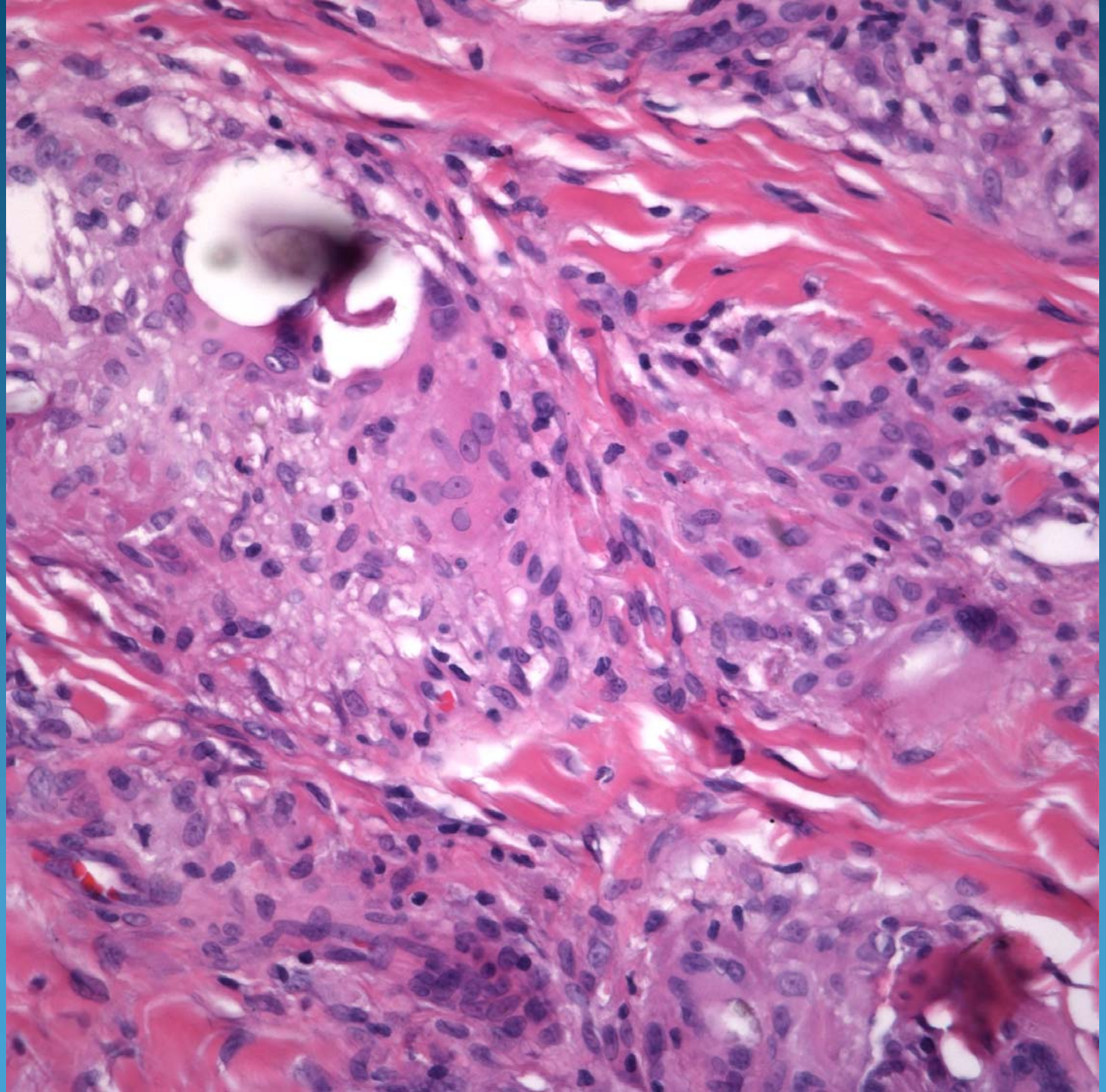

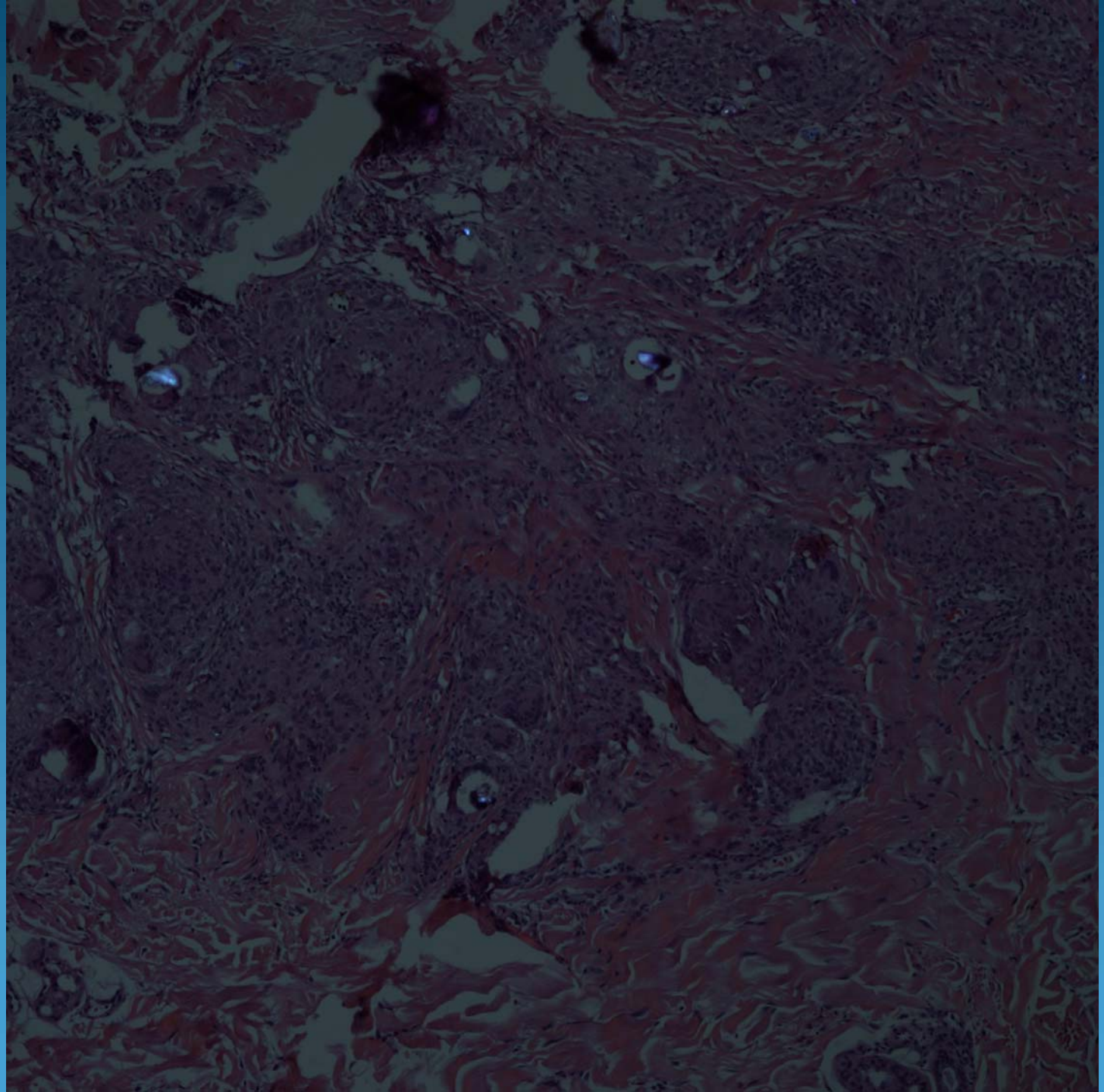

Sarcoidal-like Foreign Body Giant Cell Reaction with Polarizable Refractile Material

Pearls

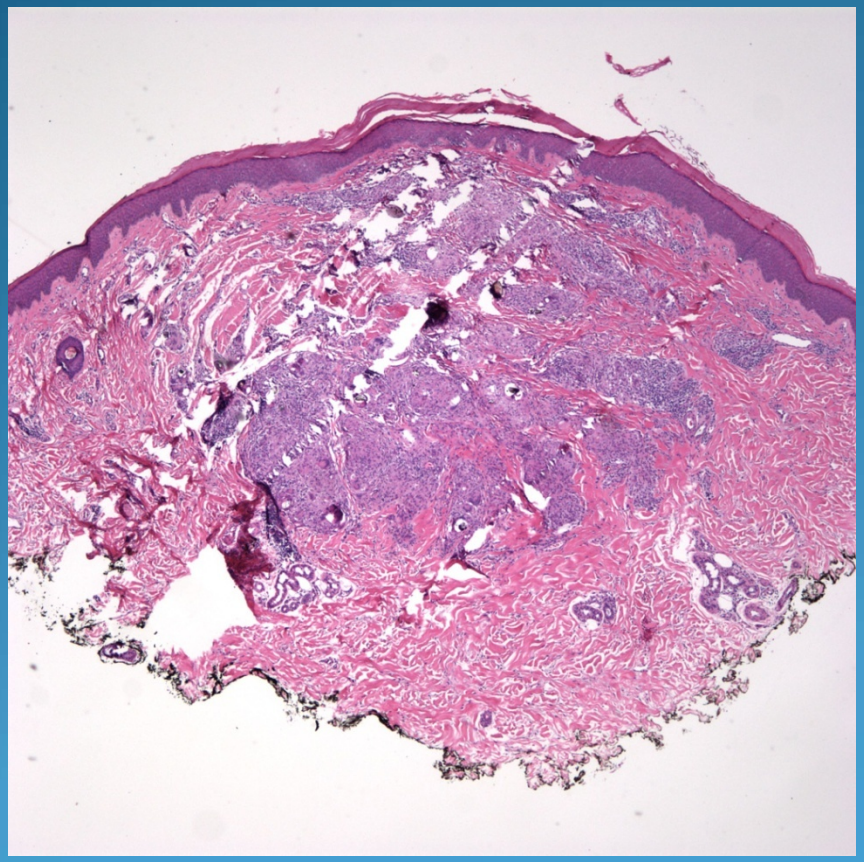

- Granulomas with foreign body-type giant cells
- Look for knife chatter
- Polarization may reveal refractile material
- Obtain special stains (AFB, Fite, PAS/GMS) to rule out infection
- Rule out underlying sarcoidosis